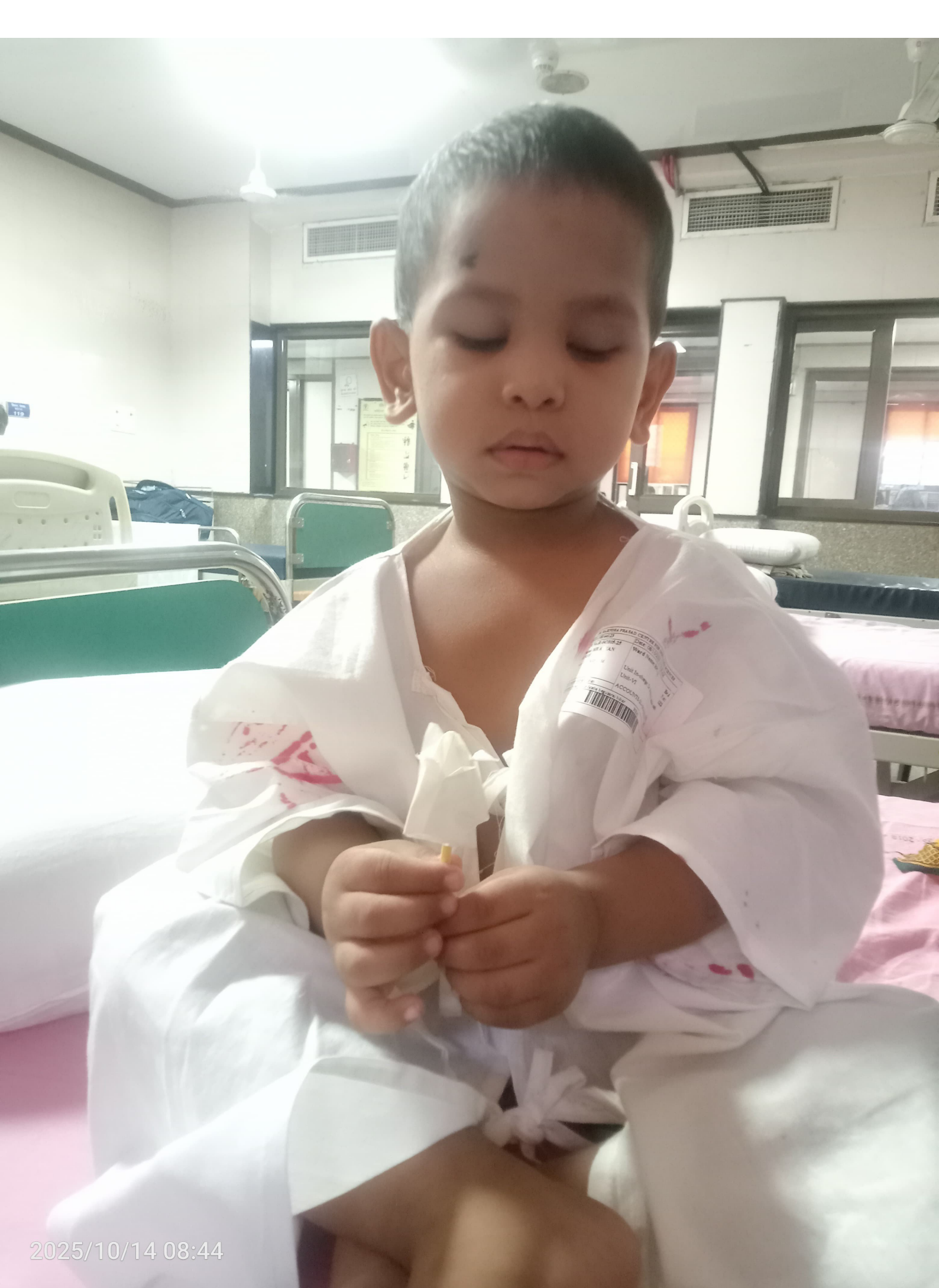



2025/10/14 08:44




अ० मा० आ० सं० अस्पताल / A.I.M.S. HOSPITAL
बहिरंग रोगी विभाग / Out Patient Department



स्मॉकिंग से अवरुद्ध सुवर्ण क्षेत्र है। / SMOKING IS PROHIBITED IN HOSPITAL PREMISES

रोगी विभाग / क्लिनिक
 UHID: 106564818




Dept No: 2025-0030023385

कक्षा / कमरा / Room
 C 218
F22

युनिट / विभाग / Unit-III, Paediatric.

रोगी का नाम / KISHOR KISHOR

पु. ति. / Wed, Sat



Reporting: 08:19:20
 20/04/2026

SO MANG
 27 8M 20 / MA (2024)
 VILL BARARI DIST MATHURA, UTTAR
 PRADESH, Pin 0 INDIA
 Ph: 9105367812
 General 18 0
 Follow Up Patient

OPR-6

रजिस्ट्रेशन नं./O.P.D. Regn. No.

वय / Age

पता / Address

रिपोर्ट / Diagnosis


रिपोर्ट / Date

7
 13.11.24
 13.11

उपचार / Treatment

N/v on 06/5/26 @ case/acc/pat

Handwritten signature




CLEAN AND GREEN AIMS / एम आर सी ग्रीन एम्स, स्वच्छता से जगता जल
 अंगदान-जीवन का बहुमूल्य उपहार / ORGAN DONATION - A GIFT OF LIFE
 O.R.B.O., AIMS, 26588360, 26593444, www.orbo.org Helpline - 1060 (24 hrs service)





अ० मा० आ० सं० अस्पताल / A.I.M.S. HOSPITAL
बहिरंग रोगी विभाग / Out Patient Department



स्मॉकिंग से अवर प्रवृत्तन कता है। / SMOKING IS PROHIBITED IN HOSPITAL PREMISES

रोगी विभाग / कक्षा
UOID-106564818



कक्षा / कमरा
F22


Dept No: 2025-0030023385

Unit-III, Paediatric.

रोगी नाम / केशव KISHOR

SO MANG
 27 8M 20 / MA (F)
 VILL BARARI DIST MATHURA, UTTAR
 PRADESH, Pin 0
 Ph: 9
 General 1s 0
 Follow-up Patient

रुग्ण नाम, Wed, Sat



Reporting: 08:19:20
 20/04/2026

OPR-6

रजिष्ट्रेशन नं० / O.P.D. Regn. No.

वय
 Age

पता / Address

रोग / Diagnosis


रोग / Date

7
 13.11.26
 13.11

उपचार / Treatment

N/v on 06/5/26 @ case/acc/pat

1
 Hize




CLEAN AND GREEN AIMS / एम आ यही संकल्प, स्वच्छता से काया रक्ष्य
 अंगदान-जीवन का बहुमूल्य उपहार / ORGAN DONATION - A GIFT OF LIFE
 O.R.B.O., AIMS, 26588360, 26593444, www.orbo.org Helpline - 1060 (24 hrs service)





अ० भा० आ० सं० अस्पताल / A.I.I.M.S. HOSPITAL
 बहिरंग रोगी विभाग / Out Patient Department



अस्पताल की अन्दर धूम्रपान बन्द है। / SMOKING IS PROHIBITED IN HOSPITAL PREMISES

OPR-6

बास विभागा विभाग / UHID:108564918

कमरा / Room C 216
 Queue / संख्या F11
 Unit-III, Paediatric.

कार्डिनल पंजीकृत नं० / O.P.D. Regn. No. _____

Dept No: 20250030023385

किशोर किशोर / KISHOR KISHOR

S/O MANO
 2Y 5M 4D / M(पुरुष)
 VILL BARARI DIST MATHURA, UTTAR
 PRADESH, PIN-0 INDIA
 Ph: _____ General Rs 0
 Follow Up Patient



Reporting: 09.02.27
 31/01/2026

आयु / Age

पता / Address

रिपोर्ट / Diagnosis

उपचार / Treatment

दिनांक / Date

51
 12-4-26

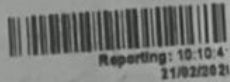बास विभागा विभाग / UHID:108564918

कमरा / Room C 216
 Queue / संख्या F31
 Unit-III, Paediatric.

Dept No: 20250030023385

किशोर किशोर / KISHOR KISHOR

S/O MANO
 2Y 5M 25D / M(पुरुष)
 VILL BARARI DIST MATHURA, UTTAR
 PRADESH, PIN-0 INDIA
 Ph: _____ General Rs 0
 Follow Up Patient



Reporting: 10.10.4
 21/02/2021

Details in notebook.

FN in Peds OPD on 14/03/26 c
 CBC, LFT, MET report,

13.5
 66



PH-157
 20250030023385

CLEAN AND GREEN AIIMS / एका का यही संकल्प, स्वच्छता से स्वास्थ्य कल्प

अंगदान-जीवन का बहुमूल्य उपहार / ORGAN DONATION - A GIFT OF LIFE

O.R.B.O., AIIMS, 26588360, 26593444, www.orbo.org Helpline - 1060 (24 hrs service)



www.aiimshospital.in



अ० भा० आ० सं० अस्पताल / A.I.I.M.S. HOSPITAL
बहिरंग रोगी विभाग / Out Patient Department

अस्पताल में अंधार धूम्रपान मना है। / SMOKING IS PROHIBITED IN HOSPITAL PREMISES

बाह्य चिकित्सा विभाग
UHID: 108564911

कमरा / Room C-210
Queue / संख्या F14
Unit-I, POC

OPR-6

Dept No: 20250030023385
Clinic No: 2025/P/OC/304

किशोर किशोर / KISHOR KISHOR

रोगी सं./O.P.D. Regn. No. _____

पता / Address _____

S/O MANO
2Y 6M 27D / M(पुरुष)
VILL BARARI DIST MATHURA, LITTAR
PRADHANSABAD, INDIA
Ph: 9811111111
Follow up at _____

General Rs. 0

Reporting: 01:50:26
13/03/2026

रिपोर्ट/Diagnosis

दिनांक / Date	उपचार / Treatment
13-14 वैद्य	N/V : 13/4/2026 E CBC RFT LFT ↓
13-14	R/V 23/4/26 CBC, RFT, LFT
	Dr. Nishu JR

बाह्य चिकित्सा विभाग
UHID: 108564911

कमरा / Room C-210
Queue / संख्या F11
Unit-I, POC

Dept No: 20250030023385
Clinic No: 2025/P/OC/304

किशोर किशोर / KISHOR KISHOR

S/O MANO
2Y 7M 17D / M(पुरुष)
VILL BARARI DIST MATHURA, LITTAR
PRADHANSABAD, INDIA
Ph: 9811111111
Follow up at _____

General Rs. 0

Reporting: 01:40:46
13/04/2026

CLEAN AND GREEN AIIMS / एम्स का यही संकल्प, स्वच्छता से काया कल्प
अंगदान-जीवन का बहुमूल्य उपहार / ORGAN DONATION - A GIFT OF LIFE
O.R.B.O., AIIMS, 26586360, 26593444, www.orbo.org Helpline - 1060 (24 hrs service)





अ० मा० आ० सं० अस्पताल / A.I.I.M.S. HOSPITAL
 बहिरंग रोगी विभाग / Out Patient Department



अस्पताल में अग्नय धुआकन मना है। / SMOKING IS PROHIBITED IN HOSPITAL PREMISES


रोगी विवरण / Patient Details

UHID: 108564816

कमरा / Room

C 218

OPR-6



Dept No: 20250030023385

Queue /
संख्या

F34

Unit-III, Paediatric

पंजीकृत सं० / O.P.D. Regn. No.

रोगी नाम / KISHOR KISHOR


उम्र /
Age

पता / Address

S/O MANO
27 SM 180 / M/38y

बुध, मंग, Wed, Sat

VILL BARARI DIST MATHURA, UTTAR



Reporting: 09:00:23
14/03/2023

PRAGATI, INDIA

PN: 2 General Rs 0

Follow-up Patient

रिपोर्ट / Diagnosis

दिनांक / Date

01

12. Kg

उपचार / Treatment


N/V in OPD - 21/3/2023 - CBDRH/UF.
Swami
 SA.



CLEAN AND GREEN AIIMS / एम्स का गरी संकल्प, स्वच्छता से जाया कल्प
 अंगदान जीवन का बहुमूल्य उपहार / ORGAN DONATION - A GIFT OF LIFE
 O.R.B.O., AIIMS, 26588360, 26593444, www.orbo.org Helpline - 1060 (24 hrs service)



meraaspatal.nhp.gov.in



www.orbo.org Helpline - 1060 (24 hrs service)

29/4/26

lt eye EORB post enucleation
completed 10 cycles of HD-CEV

Radiotherapy on going

Day 3 of RT today

± ep vomiting

No mucositis, facial swelling,
rash

CBC (27/4/26)

9-7
5700
1400
1-28L

Adv.

- Tab EMSET 3mg PO ~~to~~ TDS
- Tab LANZOL JUNIOR 1 tab PO OD
- N/A on 6/5/26 \bar{c}
CBC/LFT/UA

LH04052601684 108564918

LC0405262400 108564918



Mr KISHORKISHOR

Handwritten signature

Dr. ANJALI BARUA
DM Senior Resident
Dept. of Pediatric Oncology
AIIMS, New Delhi

11.4.26

EOAB | post endocytosis
completed 9# 40 CAV
[24.3 - 25.3.25]

EOAB | pending IV

CT simulation
done ✓

due for cycle 10

mechmo labs - (ii)
11.4.26

Advise (i) cycle 10 date - 14/4/26 - 15/4/26
"earliest slot"

inj. Emset 2mg iv

inj. nexa 2mg iv

↓
inj. VCAV 0.3 mg iv slow push

inj. CARBORHATIN 335 mg / 100ml NS
over 1hr

21/02/26

No mouth ulcers
2% betadine gargle
- Ely's bath
- Personal Hygiene
- on set back. All Day
C/O cough & cold

Δ 4 EOBs / Post 7# HSCV

Planned for E7. Day ①

Due for 8th HSCV.
① Nasal saline drops 2nd Ltr. 2 days x 3 drops

Advice: ② Epp. Cefixime 5ml 10 ML x 3 days -

Reg Euvast 2mg IV
Reg Dexam 2mg IV

Reg VCR 0.3mg dose 2x week - ①

Reg Catecholamin 35mg in 100ml NS 5x one 1hr - ①

Reg Sitopride 145mg in 400ml NS 5x one 2hrs ① ②

Post Care:

Epp. Euvast (2mg/5ml) 5ml 6 TDS x 3 days

1. Dexam (4mg) 1/2ml PO BD x 3 days

- Reg 4-CAP 60mg q/c OD from ① till HSCV

- Continue dexam as advised.

- V/U in Peds OPD on 14/03/26 = call, UFI, APT
21 report

Amul

20/02/26
8.1
6510
2.34L
ANC-1500

20/02
Urea/L_r - 10/02

UFI, UFI - ①

Give dexam

date:

27/2/26

28/2/26



2/2/26
facies

~~2/2/26~~
D1 + D2
D3
D4
D5
D6
D7
D8
D9
D10
D11
D12
D13
D14
D15
D16
D17
D18
D19
D20
D21
D22
D23
D24
D25
D26
D27
D28
D29
D30
D31
D32
D33
D34
D35
D36
D37
D38
D39
D40
D41
D42
D43
D44
D45
D46
D47
D48
D49
D50
D51
D52
D53
D54
D55
D56
D57
D58
D59
D60
D61
D62
D63
D64
D65
D66
D67
D68
D69
D70
D71
D72
D73
D74
D75
D76
D77
D78
D79
D80
D81
D82
D83
D84
D85
D86
D87
D88
D89
D90
D91
D92
D93
D94
D95
D96
D97
D98
D99
D100

25/02/2026

▷ ② EORR

POST 7 ≠ HD-COV

scheduled for CBRT → cancelled

no URI

$$\text{CBC (20/02/26)} - 8.10 \left) \frac{6310}{1500} \left(294 \times 10^3 \right)$$

o/e - chest - clear

Adv:

- stop LEVOCETRIZINE (5ml / 2.5mg) 4ml OD + 7 days
- no cont SEPTRON
- next visit → 2/3/2026 | Amrino

CBC = 8.7 } $\frac{4050}{4/8/1/1}$ $\frac{78K}{}$ ANC = 1782

13/3/2024

Repeat CBC / LFT / RFT

Dr. Anshu WASHNEY
 Consultant, Paediatrics
 All India Institute of Medical Sciences
 New Delhi

14/3/26

No mouth ul
 2% betadine
 Sitz bath
 Personal
 on septon
 No fever

$$8.50 \left) \frac{4260}{270}$$

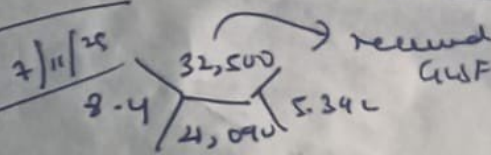
RA/LA:
 (13/3)

8/11/25

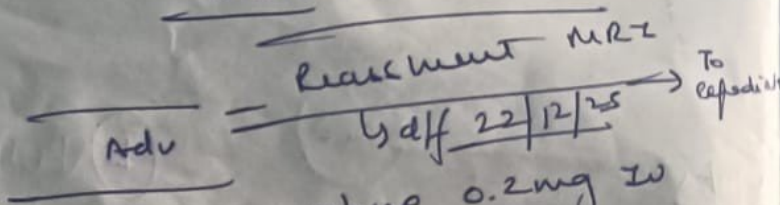
- Mouth ulcer
- 2x betadine gargles
- Sitz bath
- on sepsis
- personal hygiene
- No fresh complaints

do (L) EORLB / Post and HOLEU

due for 3rd HOLEU



(15) → MCH anaemia
new → 72.7



- i.v. vincristine 0.2mg IV slow push

dated on 10/11/25

- (D1) i.v. carboplatin 310mg in 200ml NS IV over 1 hour
- (D1) i.v. etoposide 130mg in 250ml NS IV over 2 hours
- (D2) i.v. GCSF 55mcg SC OD x 5 days

lost chems :

- Spp. cement (2mg/sw) 4ml tid x 3 days
- T-Dexa 4mg 1/2 tab BD x 3 days

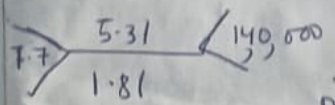
- RT re-examination

- 14

(N/U) in OPD 26/11/25

Sumitra SW

26/11/25



- (i) i.v. VCR
- (ii) i.v. carboplatin slowly
- (iii) i.v. etoposide 2 hours
- (iv) i.v. GCSF

• Kindly get chem sheet

• RT investigation etc when you see. (IRCM)

• N/V 27 24/12/25 τ CBC / RFT/UT

• Syf (MISER) (5ml/2ml) 5ml POBDS } x3 days
• Tab DANA 2mg 1000

Nikita

Dr. NIKITA SINGH
SR Pediatrics Oncology
Dept. of Pediatrics Oncology
All-MS, New Delhi

11/10/25

C10. @EORB

C10. @EORB

→ retained 1 cycle HPCEV.

no complaints currently.

→ vitals stable

RS: NE = BS clear.

CV: S12 hear of

PA: JNT

CNS: uc 15/15.

CBC → $\frac{9390}{1940} \times 3.85L$

RFT/CFT → @

due for 2nd HPCEV

Plan

→ PET admed to admission

18/10/25

to 19/10/25

→ IV Emetrol 1.5mg stat

→ IV dexa 1.5mg stat

D1 → IV vincristine 0.2mg slow push in 100ml NS over 30 min

D1 → IV carboplatin 390mg in 100ml NS over 30 min

D1, D2 → IV Epoetin 132mg in 100ml NS over 30 min

D3 to D7 → Int G-CSF 55mcg SC QD

11

date for HPCEV

Dr [unclear] 19/10/25

#2 tentative date → 8/11/25
 → 9/11/25
 HDCEV
 CEV
 Kindly not

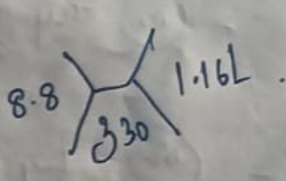
8/11/25 - 9/11/25



np 3/11/25
 at 2pm in 1st
 2 CH/11/25

- 3/11/25
- No mouth ulcer
 - gargles
 - Sitz bath
 - on Septon
 - Personal hygiene
 - No fresh complaints.

bus
 in
 (L) EORB :
 cycle-3 HdCEV dated 8/11 and 9/11.



Advice:

1. Inj. G-CSF 55mcg S.C OD x 5 days ^(D1) 3/11/25 gms
2. Rpt CBC on 7/11/25
3. OPD on 8/11/25.

Amjmm
 SR.

Post chemo

→ d/p . Emet 2mg/5ml

4ml |-----| x 3 da

- T. Dexa 4mg 1/2 ----- 1/2 x 3 da

→ fu on ~~18/10/25~~ 29/10/25

→ RT registration

- HOD n/r
- had already been given
- To collect report
PCT, report
urgently.
or



29/10/25

- No mouth ulcer
- 2x betadine gargle.
- Sitz bath
- on sepsan
- No fresh complaints
- personal hygiene.

Δ: Ⓢ COAB
lost 2# HDLV
(18/10 - 19/10).

no active complaints
reassessment MDR pending
date not taken

~~1.4~~ 8.4 > 6080 < 1.98L
2230

• C#2 tentative da
↓ (HDLV)
Kindly MDR

- N/V 3/11/25

3/11/25
- No mouth ulcer
- gargles
- Sitz bath
- on sepsan
- personal hygiene
- No fresh complaints

4/10/25

40 @ EORB / Post 1st # HDCEV
19/9 - 20/9/25

No complaints - → will be due for
Blood Tx not done next cycle ~ 11/10/25

Adv

(N/v) on 11/10/25
CBCL/FT/UF7

Shuntro
sr.

1110

11/10/25

- 2-1- Betadi ne gangle
- 9/2 bath - oo - enplamad
- ~~oo~~ Septan (Not taking)
- C/O - cold
NO preser
- file incomplete

Diagnostic Work UP & Risk Stratification

2 yrs old Boy

C/O (L) eye leukocoria x NOV 2025

LE → large mass in post aspect of retina
USG → Intra lesional aspect cent

MRC/RC → T2 Hypo Intense IO lesion, ON Not Enhanced

EUA → (L) eye of RB

upfront Enucleation ⇒ 5/8/25

HPE → Poorly differentiated RB, Tumor Extensive/
Infiltrating the choroid
Infiltrating entire length of ON, cell end neg
Sclera not Breached. 18mm

- Viral marks not seen.

- PET den on 10/3/25

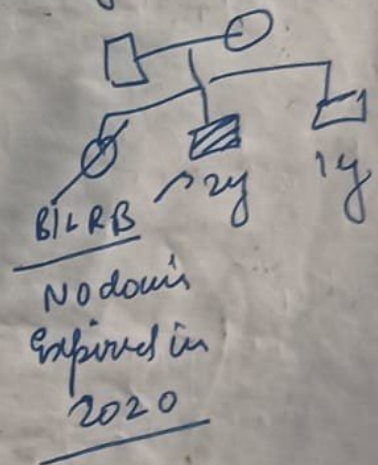
- BMA + CSF → not involved → acellular
Biopsy → not involved

Name of treatment protocol

(L) EORB / Familial /

genetic testing ⇒

Family history ⊕



child had collection in BM site.

USL → 8/5/15 B/L shows 1cm hetero coloz
local site

on augmentation since 8/9/25.

↓
currently swelling ↓ in size @ BM site.

child clinically well after start

LC1009252694 108564918

LH10092502011 108564918

Mr KISHORKISHOR

o/c: (4E) → B/L local area reduces + ul
(R) side → tenderness + ul

To start chemo after infection resolves

Adv
(1) syp. augmentation 6ml BD x 7 day

(2) syp. Par (250mg/5ml) 3ml SOS if T > 100°F

(3) syp. sepran (40mg/5ml) 6ml alternate days

(4) PET CT d/f 17/9/25

(5) N/A in OPD on 15/9/25 at 2pm

- Sitz Bath / Betadine gargles / mouth
(6) ceprax

Signature
Dr. [Name]
Department of Pediatrics
All India Institute of Medical Sciences, New Delhi-110029

PHONE NO

DATE OF TR

8/9/25
21349
341L
10.1
H2247.

8/9/25

POC discussion

① Collect BM A + Biopsy report

② Collect CSF report

③ PET dated on 10/9/25

④ Bone marrow site / Cellulitis / Abscess
↓
No fever
Local site warm & tender
Reds usually

① USy local site

② Aspirate → send for culture

③ X Ray Pelvis? (osteomyelitis)
AP Lateral

④ Try Augmentin 20mg iD (B)

⑤ CBC / LFT / RFT / Blood C/S
P/I/NR/APTT. VBG

⑥ Plan to give HD CEV 12# H16RT

⑦ RT registration in 1RCH

⑧ HIV / Mbs Ag / Anti Mbs / Anti Her
genetic 5 testing for RB 7 gene

38
27/4/26

डा. बी. आर. अम्बेडकर संस्थान रोटरी कैंसर अस्पताल
Dr. B.R. Ambedkar Institute Rotary Cancer Hospital
अथवा आरम अस्पताल / A.I.I.M.S. HOSPITAL

OPR-8

Patient Department
IG PROHIBITED IN HOSPITAL PREMISES

DR. B.R.A. IICLAHMS, NEW DELHI
IRCH No. 359360
Clinic Radiotherapy Evaluation
Dept. RADIATION ONCOLOGY
General
नाम किशोर किशोर
Name KISHOR
S/O-MAHO
Phone No. 5
UHID-108564918
Sex/Age M/2Y
Room 13 (Shift Morning)

ब-रो-वि. पंजीकृत सं./ O.P.D. Regn. No. RT-185968



लिंग / Sex	आयु / Age	जन्म तिथि / Date of Birth
		Prof. A Biswas

निदान / Diagnosis: (L) Eye FORB s/p Surgery (enucleation) (c/o/as)

दिनांक / Date: 27/4/26
उपचार / Treatment: s/p IO HOPEV (14/4/26)

27/4/26
RT Date & Time (GA)
28/4/26 - 9AM
29/4/26 - 9A
30/4/26 - 9A
07/05/26 - 9AM

Radiation Planning Note
Patient has been planned for post-op RT to a dose of 40Gy/20#/4 weeks to (L) orbit using VMAT technique using 6MV X-ray energy on ELEKTA VERSA HD. ↓ GA

- Adv - i) RT payment - Rs. 750/- (13)
- ii) Skin care explained - do not apply cosmetic lotion in irradiated area.
- iii) Refresh eye drops B/l eye - 2 drops each eye TDS
- iv) R/o weekly with (AC, LFT, KFT) (Patient admitted in MRO ward).
- v) Syrup. Septtran 5ml po od (alternate days)
- vi) Syrup A to 2 po od 5ml. vii) Syrup Vitafol 5ml po od

अंगदान-जीवन का बहुमूल्य उपहार / ORGAN DONATION - A GIFT OF LIFE
O.R.B.O., AIIMS, 26588360, 26593444, www.orbo.org Helpline 1060 (24 hrs service)
बाहर से आने वाले रोगियों के लिए धर्मशाला की सुविधा उपलब्ध है/Dharamshala facility is available for outstation patients

AIIMS

[Handwritten signature]

⑨ EUA Examined of → younger sibling
→ mother &
- father

⑩ To follow up in Peds onco OPD on
10/9/25

⑪ MDCEU protocol from daycare

⑫ Sitz Bath / Betadine gargles

Dr. VISHAKHA VASHNEY
Senior Consultant
Department of Pediatrics
All India Institute of Medical Sciences
New Delhi

10/9/25

counselled on

Hand hygiene,
th, personal
(Nails to
be trimmed).

area
(photocopy of
BMA & CSF)

do (L) EORB

metastatic w/v

↓
CSF → acellular

BMA → No mets

BMBx → awaited

PET CT → d/f 17/9/25

To start
after
8/9/25
213349
10.1
H221

15/09/25

Generally done

① EORB

No fresh complaints

Bone marrow site

(ASIS)

No discharge/
swelling/tenderness

No 1/2 fever

- PEI dated

17/09/25

1/2 E → Alptrin

chest-clear, NVB's

Wt → 11kg

Nopalles

1/2 A - soft, non-tender

BGA → 0.93

1/2 PSL S - Healthy

liver, spleen - not palpable

No discharge

(Check blood investigations & viral markers
prior to chemotherapy)

Date for HDCEV

19/9/25

Inj. Dexamethasone 4mg IV stat

Inj. Emeset 4mg IV stat

Inj. Vincristine 0.2mg IV slow push → 19/9/25

Inj. Carboplatin 310mg/100ml NS IV over 1hr. D1

Inj. Etoposide 130mg/250ml NS IV over 2hr. D2

100mg x 2

Post chemo

Syp. Emeset (4mg/5ml) 5ml PO QDS x 3 days

Tab. Dexamethasone 4mg Dexamethasone 4mg 1 tab BD x 3 days

On oral antibiotics

1/17

N/V

Ady

HIV

HBS

CBC

CRP

8/9/25

10


m/bw

INT. G-CSF 55mg q/OD x 5 days


ender

→ 11kg
→ 0.53

ke 12
chem



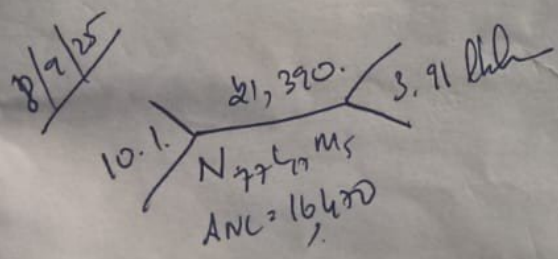
BD x 3 days



~~N/V~~ ————— (OPD) 04/10/25 Saturday with
 Adv CBC, LFT, RFT 1

- HIV (ICIC, Romm)S
- HBS Ag, anti HCV, anti HBs
- CBC, LFT, RFT
- (SmartLab)

Chul
 Dr. RUKSAMA SIDHQUE P.R.
 DM Resident
 Pediatric Oncology
 AIIMS, New Delhi



26/11/25



(L) FORB

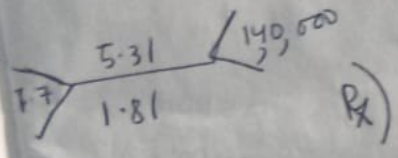
initial (L) group F

↑ support consolidated

- HPR - poorly differentiated AB
- infiltrates entire length of ONJ
- cut end Negative
- axial brush - Negative
- infiltrates closed

single 4 color

To epodiate



Prescription
 In GEMET. 2mg IV stat
 In DEXA. 2mg IV stat

- (i) In VCR 0.2 mg IV slow push D₁
- (ii) In CARBO PLATIN 300 mg in 100ml NS IV slowly over 1 hour D₁
- (iii) In ETOPOSID 130 mg in 300ml NS D₁ / D₂ 2 hour
- (iv) In G-CSF 55 mcg - D₄ (of chem) D₅ D₆ D₇ D₈

Chemotherapy
 6/12/25 - 7/12/25
 IV slowly over

Nikhil

15

Date:

NEUROIMAGING

hi

CT

Right eye

Left eye

CG (Orbit)

22/3/25

EVA

done

↓ Prof. Sharma
Dr. Deep / Dr. Tapashree /
Dr. Disha

MRI

OT

OS

(

WNL

Corneal haze ⊕

MRI (Brain)

USG

More than 50% globe involved
mass
Spikes slo VA/VE

PET

Fn

Globe ⊕
Disc, macula healthy

Media haze ⊕
Mass seen inferiorly

DBM

No loss of touch

R7 / 35968

DR. B. R. A. INSTITUTE 3593

(R) WNL
(L) Emulation x 5/8/25

29/10/25 ✓

-10995

↓
replaced copy
for group RB τ
HRE in HPE

(HDCEN)
2[#] cycle chemo
(abt 19/10)

↓
(D) Propy done
(22/8/25)

Delate (R)
PRC

↓
(153) OPTOS CP

i prg
just for
DR. Suresh

(not cooperative)

Out for EVA

(35A) Dr. Kalubla

19/11/25
~~Had 2A~~
OT 74/11/25

3/11/25

29 chemo 8/11

19/11/25

EVA done ↓ unit-4 ↓ Prof. Bharamba
or submit

19/11/25
① WNL
② 4P Enucleation 5/8/25
(4v 3P & RB, NKF as 4PE)

22/8/25 - Biopsy :-

8P ③ HDCEV last - ~~10/11/25~~ 8/11/25

Report 142B
NITIA

① WNL

② 4P mycin 370 350 → stop.

Plup & Bx reports after 2 hrs (Wednesday) 2 pm
from 7:30 am
(ocular pathology)

No evidence of malignancy

Med. Miflodex 7M
020 ① X 3 weeks

fully
growth
unz

Alla Santhos (med) 143
Catherine Lumbrey
26/11/25

Date:

Diagnosis:

Met

Family h/o RB

likely had B/L RB
diagnosed at 3y of age

Management:

Adv:

RR 1 gen test
= ~~opt~~ option of
ultra vious chemotherapy /
enucleation explained
- opted for enucleation

35A
D/F
enucleation
①

Histopathology findings:

Dr Tapashree
Mr

Dr

BOA

26/7/25

7:30 AM

Ward 7A

Dr De Sena Sen

curlic layer 70% is infarcted, but end layer
fine but highly likely that there may
be some infarctus.

Med
27/7/25